

# UK Biobank

## Imaging modality Cardiovascular Magnetic Resonance (CMR)

---

Version 1.0

<http://www.ukbiobank.ac.uk/>

30<sup>th</sup> Oct 2015



This document details the procedure for the CMR scan performed at an Imaging assessment centre for UK Biobank.

## Contents

1. Introduction.....	1
2. Participant Preparation.....	2
3. CMR equipment.....	3
4. CMR modality measurement.....	3
5. QC protocol.....	7
6. Data collected.....	7

## 1. Introduction

**1.1:** This manual details the procedure for the CMR measurement at a UK Biobank Imaging Assessment Centre.

**Table 1:** Sequence of assessment visit

	Visit station	Assessments undertaken
1	Reception	<ul style="list-style-type: none"> <li>Welcome &amp; registration</li> <li>Generating a USB key for Participants</li> </ul>
2	Eligibility Section	<ul style="list-style-type: none"> <li>Eligibility questionnaire</li> <li>Consent</li> </ul>
3	Imaging scans	<ul style="list-style-type: none"> <li>Cardiac MRI scan</li> <li>Body MRI scan</li> <li>Brain MRI scan</li> <li>Whole body DXA scan</li> <li>12-lead ECG</li> <li>Carotid ultrasound</li> </ul>
4	Touchscreen	<ul style="list-style-type: none"> <li>Touchscreen questionnaire</li> <li>Hearing Test</li> <li>Cognitive function tests</li> </ul>
5	Interview & blood pressure	<ul style="list-style-type: none"> <li>Interviewer questionnaire</li> <li>Blood pressure measurement</li> <li>Measurement of arterial stiffness</li> </ul>
6	Physical measurements	<ul style="list-style-type: none"> <li>Height (Standing and Sitting)</li> <li>Hip &amp; Waist measurement</li> <li>Weight and Bio-impedance measurement</li> <li>Hand-grip strength</li> <li>Ultrasound Bone Densitometry</li> <li>Spirometry (Lung function test)</li> </ul>
7	Sample collection & exit	<ul style="list-style-type: none"> <li>Blood, urine and saliva sample collection</li> </ul>

**1.2:** At the start of their visit, each participant is issued with a USB key at the Reception station. This contains Participant ID, name, date of birth and gender. As the participant progresses between stations the USB key acts as an identifying token. The USB key is encrypted so can only be read by assessment centre computers. None of the participant's test data is transferred to the USB key. At the end of the assessment visit all identifying data on the USB key is removed.

**1.3:** This procedure is performed by a radiographer who has received suitable training and has been granted the relevant module permissions.

## **2. Participant Preparation**

**2.1:** Electrodes (for the ECG measurement) are attached to the participant prior to the CMR (see ECG explanatory documentation for further details of correct positioning of the leads).

**2.2:** The participant is fully informed prior to the scan of what the MRI scan entails and the importance of them keeping still whilst in the scanner. They are also given instructions on how to hold their breath in certain sections during the scan.

**2.3:** A pillow is placed underneath the participants' legs to minimise lumbar lordosis.

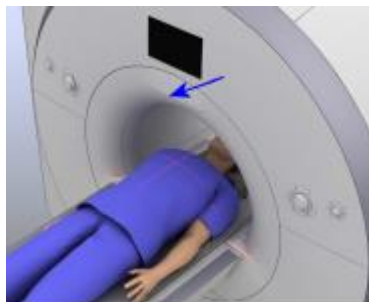**2.4:** The participant is provided with a buzzer in order for them to contact the staff at any time during the scanning process.

**2.5:** The participant is provided with appropriate ear protection for the examination (earplugs and headphones).

**2.6:** The body coil is placed onto the participant's chest, covering the whole of the chest evenly (i.e. from the shoulders down so that the heart is well covered by the coil).

**2.7:** Velcro straps are clipped into the side of the table, with the participants' arms outside of the coil.

**2.8:** The laser light on the MRI scanner enables correct participant positioning (see figure).



**Correct position of the laser light**

**2.9:** When the laser light localiser is switched on, a crosshair appears directly below the area. The table top is then moved in order to position the crosshairs directly over the area of interest.

### 3. CMR equipment

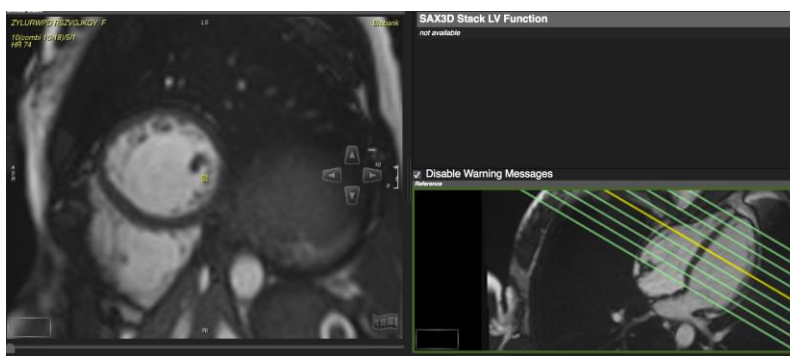
**3.1:** Cardiac magnetic resonance imaging was performed on a clinical wide bore 1.5 Tesla scanner (MAGNETOM Aera, Syngo Platform VD13A, Siemens Healthcare, Erlangen, Germany). The scanner is equipped with 48 receiver channels, a 45 mT/m and 200 T/m/s gradient system, an 18 channels anterior body surface coil used in combination with a 12 elements of an integrated 32 element spine coil and electrocardiogram (ECG) gating for cardiac synchronization.

**3.2:** In addition to the vendor's advanced cardiac package, the Shortened Modified Look-Locker Inversion recovery technique (ShMOLLI, WIP780B) was implemented on the scanner in order to perform non-contrast myocardial T1 mapping. The Cardiac Dot Engine (Siemens Healthcare, Erlangen, Germany) was used to facilitate quality for consistency of image acquisition throughout the study.

### 4. CMR modality measurement

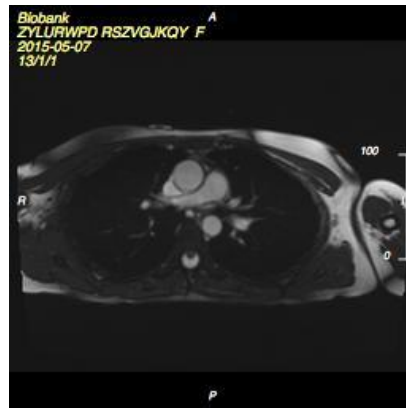**4.1:** Each participant undergoes a 20-minute CMR protocol without pharmacological stressor or contrast agent, as part of a 30- minute combined CMR and abdominal MRI protocol.

**4.2:** UK Biobank's CMR acquisitions include piloting and sagittal, transverse and coronal partial coverage of the chest and abdomen. For cardiac function, three long axis cines (horizontal long axis – HLA, vertical long axis – VLA, and left ventricular outflow tract –LVOT cines both sagittal and coronal) and a complete short axis (SA) stack of balanced steady state free precession (bSSFP) cines, covering the left ventricle (LV) and right ventricle (RV) were acquired (Figure 1).



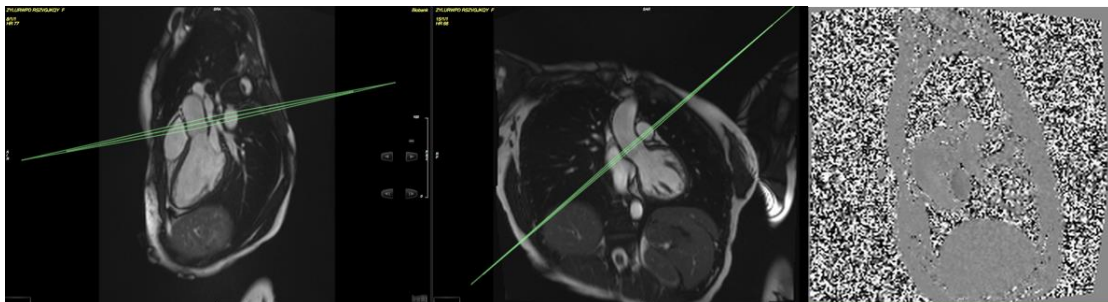
**Figure 1: Planning of the short axis cine stack covering the entire left and right ventricles.**

**4.3:** Aortic compliance can be derived from a transverse bSSFP cine at the level of the pulmonary trunk and right pulmonary artery (Figure 2).



**Figure 2: Transverse aortic cine at the level of the pulmonary trunk/right pulmonary artery**

**4.4:** A phase contrast sequence was planned on both sagittal and coronal LVOT cines to capture aortic flow and the number of valve cusps (Figure 3).



**Figure 3: Aortic valve flow imaging view planned using the sagittal and coronal left ventricular outflow tract (LVOT) cines**










**4.5:** The standard velocity encoding (VENC) was 2m/s but was adjusted based on presence/degree of turbulence seen on the LVOT cines.

**4.6:** Tagging (grid) was acquired in 3 short axis views (basal, midventricular and apical) carefully avoiding the LVOT in the basal slice. The midventricular slice position of the tagging matched the non-contrast T1 mapping short axis slice.

**4.7:** The details of the CMR sequences are summarised in Table 1.

**Table 1: Cardiovascular Magnetic Resonance protocol for UK Biobank**

Description	Sagittal anatomy	Coronal and Transverse anatomy"	Long axis cines	Short axis cines	Aortic distensibility cine	Tagging	Coronal LVOT cine	Aortic valve flow	Native T1 map
<b>Pulse sequence</b>	Trufi	Trufi	Trufi	Trufi	Trufi	GRE	Trufi	GRE	Trufi (ShMOLLI WIP780B)
<b>Flip angle (°)</b>	80	80	80	80	80	12	80	20	35
<b>TR (ms)</b>	2.6	2.6	2.7	2.6	2.8	8.2	2.7	4.6	2.6
<b>TE (ms)</b>	1.12	1.12	1.16	1.10	1.17	3.90	1.16	2.47	1.07
<b>GRAPPA factor</b>	2	2	2	2	2	0	2	2	2
<b>Slice thickness (mm)</b>	8.0	8.0	6.0	8.0	6.0	8.0	6.0	6.0	8.0
<b>Slice gap (mm)</b>	2.64	4	n.a.	2	n.a.	n.a.	n.a.	n.a.	n.a.
<b>Typical Field of View (mm)</b>	400 x 400	400 x 400	380 x 274	380 x 252	380 x 294	350 x 241	380 x 384	340 x 340	360 x 236
<b>Matrix</b>	240 x 158	240 x 158	208 x 187	208 x 187	240 x 216	256 x 174	208 x 187	192 x 173	192 x 192
<b>Voxel size</b>	1.7 x 1.7 x 8.0	1.7 x 1.7 x 8.0	1.8 x 1.8 x 6.0	1.8 x 1.8 x 8.0	1.6 x 1.6 x 6.0	1.4 x 1.4 x 8.0	1.8 x 1.8 x 6.0	1.8 x 1.8 x 6.0	0.9 x 0.9 x 8.0 (Interpolation = On, factor 2)
<b>Acquired temporal resolution (ms)</b>	n.a.	n.a.	32.64	31.56	28.00	41.05	32.64	37.12	368.28
<b>Calculated cardiac phases</b>	1	1	50	50	50	1	50	30	1
<b>ECG triggering/gating</b>	PT	n.a.	RG	RG	RG	PT	RG	RG	PT
<b>Other parameters</b>			Inline Evaluation Ventricular Function	Inline Evaluation Ventricular Function		Grid spacing 6 mm, shared phases			T1 map determined on-line.
<b>Image Filter</b>	Off	Off	Off	Off	Off	Off	Off	Off	Off
<b>Distortion Corr</b>	On (2D)	On (2D)	On (2D)	On (2D)	On (2D)	On (2D)	On (2D)	On (2D)	Off
<b>Raw Filter</b>	Off	Off	Off	Off	Off	Off	Off	Off	On: Weak, slope 25
<b>Elliptical filter</b>	Off	Off	Off	Off	Off	Off	Off	Off	Off

Description	Sagittal anatomy	Coronal and Transverse anatomy"	Long axis cines	Short axis cines	Aortic distensibility cine	Tagging	Coronal LVOT cine	Aortic valve flow	Native T1 map
<b>No of breath-holds (expiration)</b>	1	1	1 slice per breath-hold	1 slice per breath-hold	1	1 slice per breath-hold	1	1	1
<b>Orientation</b>	Sagittal (x11) PE direction = AP	Coronal (x10), Transverse (x10) PE direction = RL & AP	HLA, VLA, LVOT (sagittal) views PE direction = varies	Coverage based to apex in SA views (approximately x10) PE direction = AP	Transverse at level of pulmonary trunk/right pulmonary artery PE direction = AP	SA views (b, m, a) PE direction = AP	LVOT (coronal) view PE direction = RL	Aortic valve plane planned on both LVOT cines PE direction = AP	SA (m) PE direction = AP
<b>Image example</b>									

Abbreviations: PT - Prospective Triggering; RG - Retrospective Gating; b - basal; m - midventricular; a - apical; HLA – Horizontal long axis; VLA – Vertical Long Axis; LVOT – Left Ventricular Outflow Tract; SA – Short Axis;

## 5. QC protocol

All radiographers undergo standardised central training and scans are performed according to standard operating procedures. Every scan acquisition is assessed in real time by the operator for completeness. After data acquisition CMR images are assessed for image quality and artefacts by a senior radiographer.

## 6. Data collected

The following data were collected and are available in Showcase:

Image scans:

- Aortic distensibility images
- Blood flow images
- Cine tagging images
- Experimental shMOLLI sequence images
- Left ventricular outflow tract images
- Long axis heart images
- Scout images for heart MRI
- Short axis heart images

Other data-fields:

- Average heart rate, bpm
- Cardiac index, l/min/m<sup>2</sup>
- Cardiac output, l/min
- Ejection fraction, %
- End-diastolic volume, ml
- End-systolic volume, ml
- Height, cm
- Normalized surface area, m<sup>2</sup>
- Stroke volume, ml
- Weight, kg